



PATHOLOGICAL COMORBIDITIES

~Chiari Bridges~

ETIOLOGICAL VS. PATHOLOGICAL FACTORS

Chiari Malformation has many conditions that can be associated with it (*comorbid conditions*).

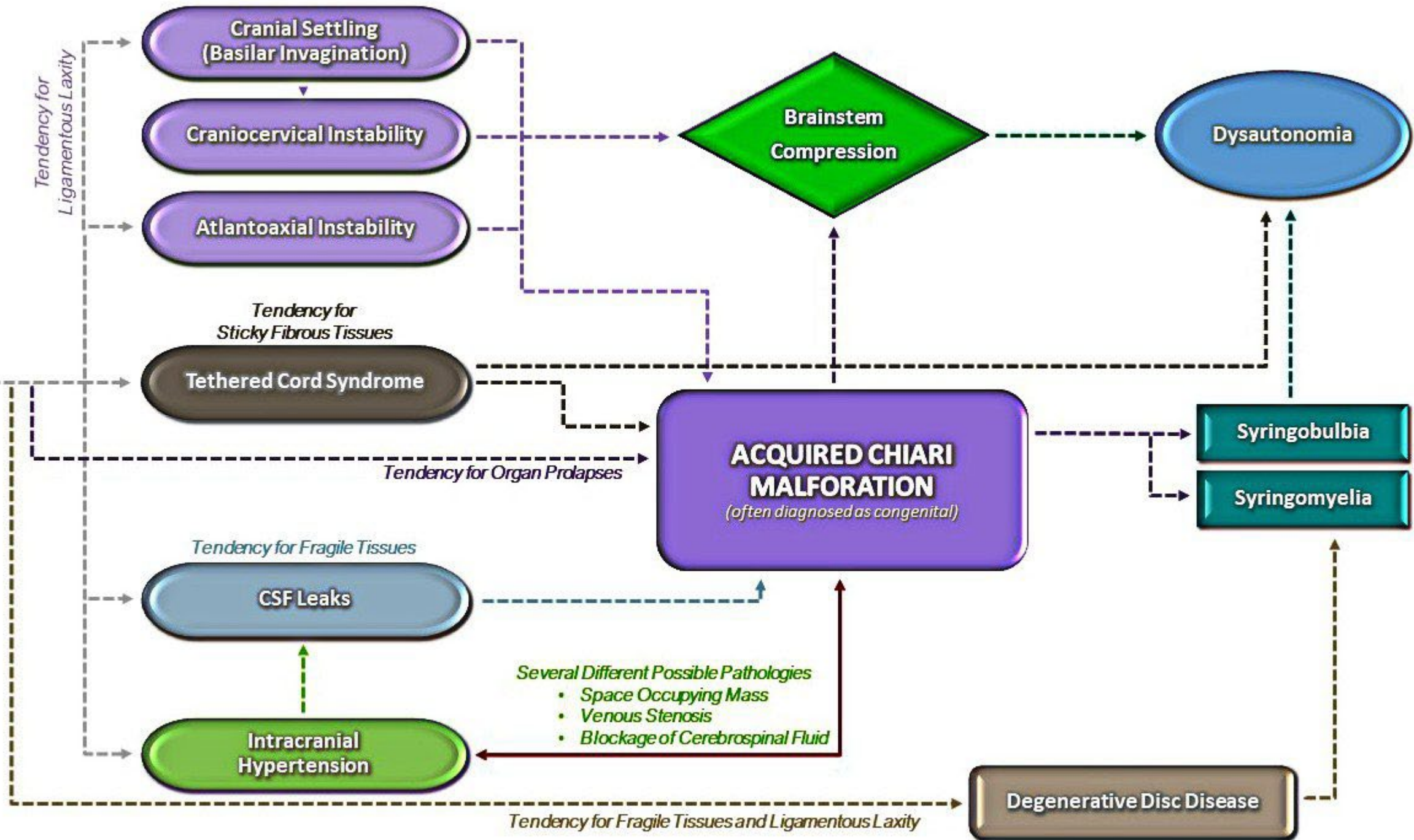
Some comorbid conditions can be at the root cause (*etiological*).

Some comorbid conditions are one of the causes along the way (*pathological*).

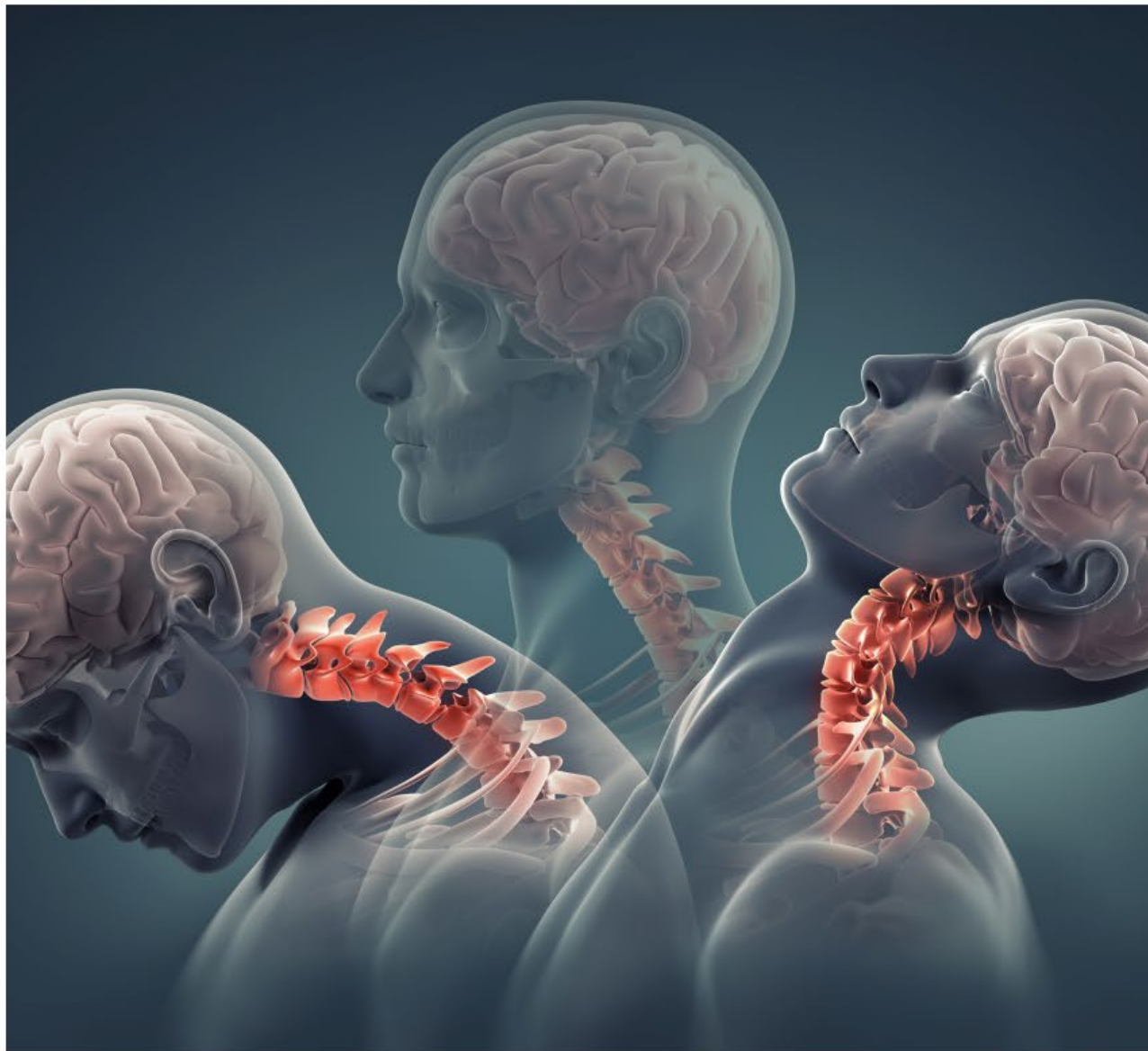Why are the cerebellar tonsils as low as they are?



EHLERS-DANLOS SYNDROME



CRANIOCERVICAL INSTABILITY

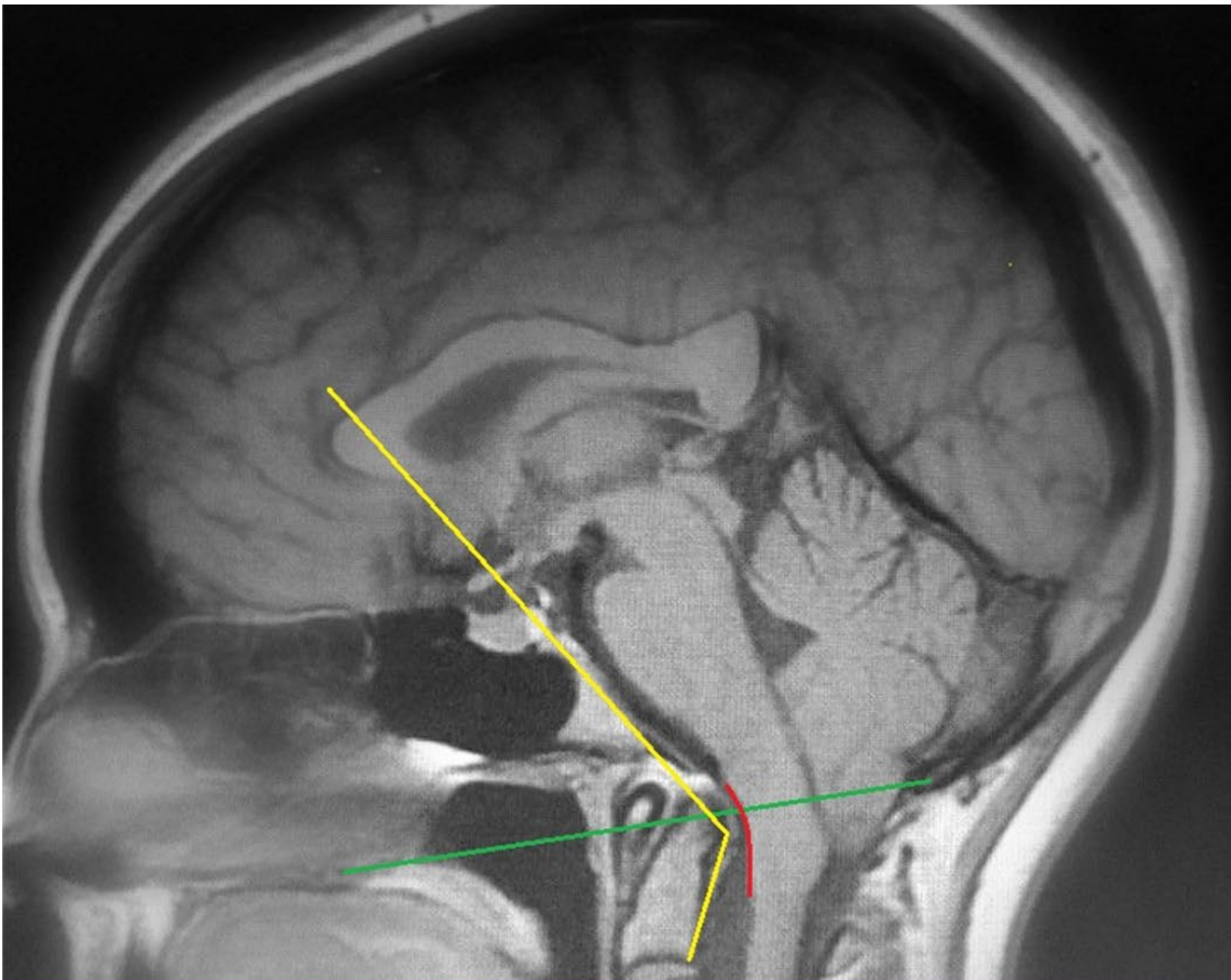


Problem in how the occiput (CO) and C1 interact.

A man with dark hair and glasses is shown in profile, looking towards the right. He is wearing a black shirt. The background is a light gray gradient.

ATLANTOAXIAL INSTABILITY


Problem in how the
C1 and C2 interact.



- Clivoaxial Angle
- Basilar Impression
- Chamberlains Line

MONRO-KELLIE HYPOTHESIS/DOCTRINE


NORMAL BRAIN


$$V_{\text{csf}} (10) + V_{\text{brain}} (80) + V_{\text{blood}} (10) = \text{CONSTANT CRANIAL VOLUME}$$


BRAIN WITH SPACE-OCCUPYING MASS (SOM)


$$V_{\text{csf}} (5) + V_{\text{brain}} (70) + V_{\text{SOM}} (20) + V_{\text{blood}} (5) = \text{CONSTANT CRANIAL VOLUME}$$

BRAIN WITH IDIOPATHIC INTRACRANIAL HYPERTENSION


$$V_{\text{csf}} (25) + V_{\text{brain}} (70) + V_{\text{blood}} (5) = \text{CONSTANT CRANIAL VOLUME}$$

BRAIN WITH VENOUS HYPERTENSION


$$V_{\text{csf}} (5) + V_{\text{brain}} (70) + V_{\text{blood}} (25) = \text{CONSTANT CRANIAL VOLUME}$$

Hyper vs. Hypo

Intracranial **HYPER**tension



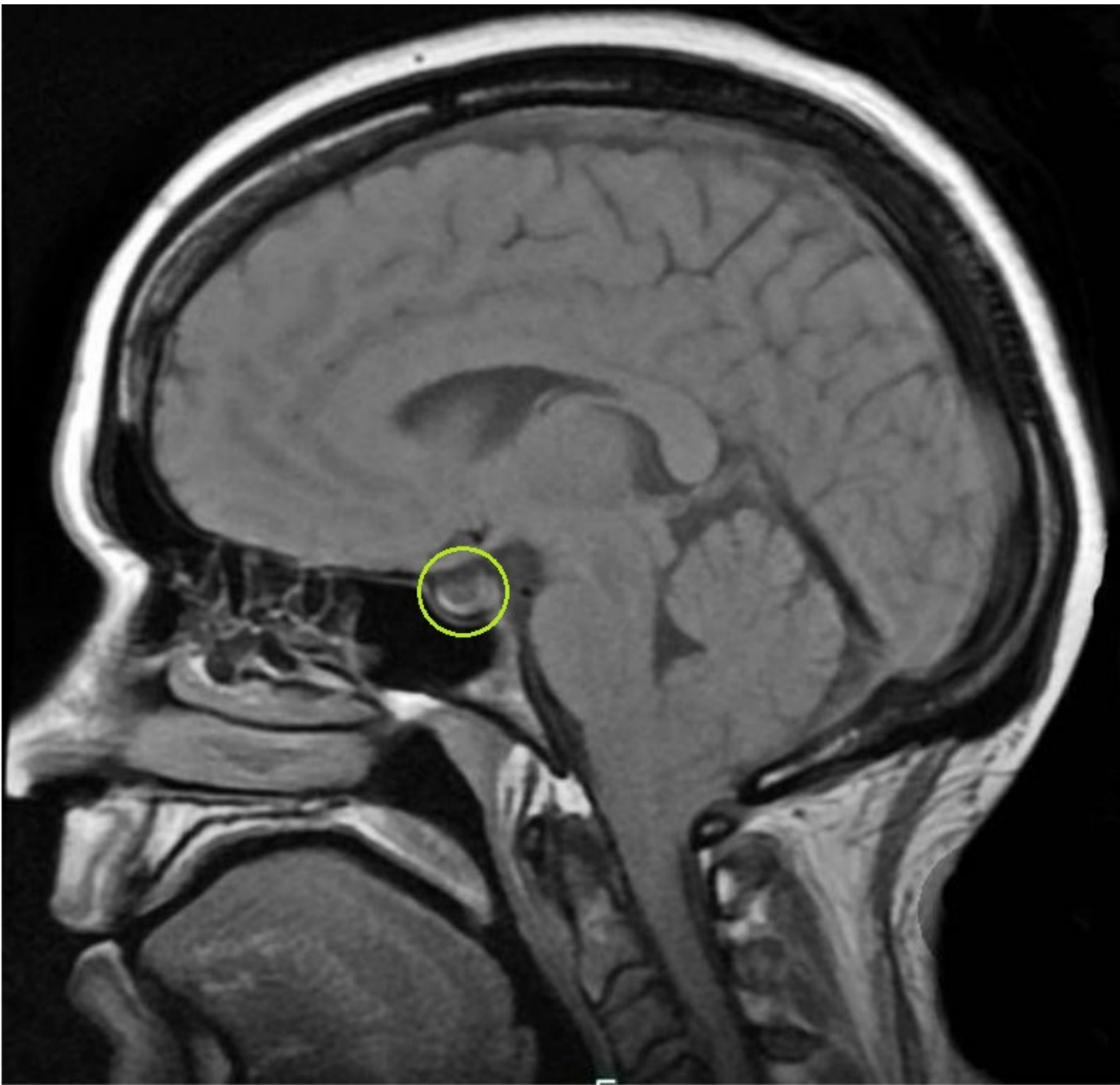HIGH
pressure

Intracranial **HYPO**tension



LOW
pressure

“normal pressure” is between 5-15 mmHg



Intracranial Hypertension

Illustration depicts the pituitary gland flattened at the bottom of the sella from the cerebrospinal fluid filled arachnoid herniation above it. The sella should have little/no cerebrospinal fluid in it.

~Courtesy of Chiari Bridges~

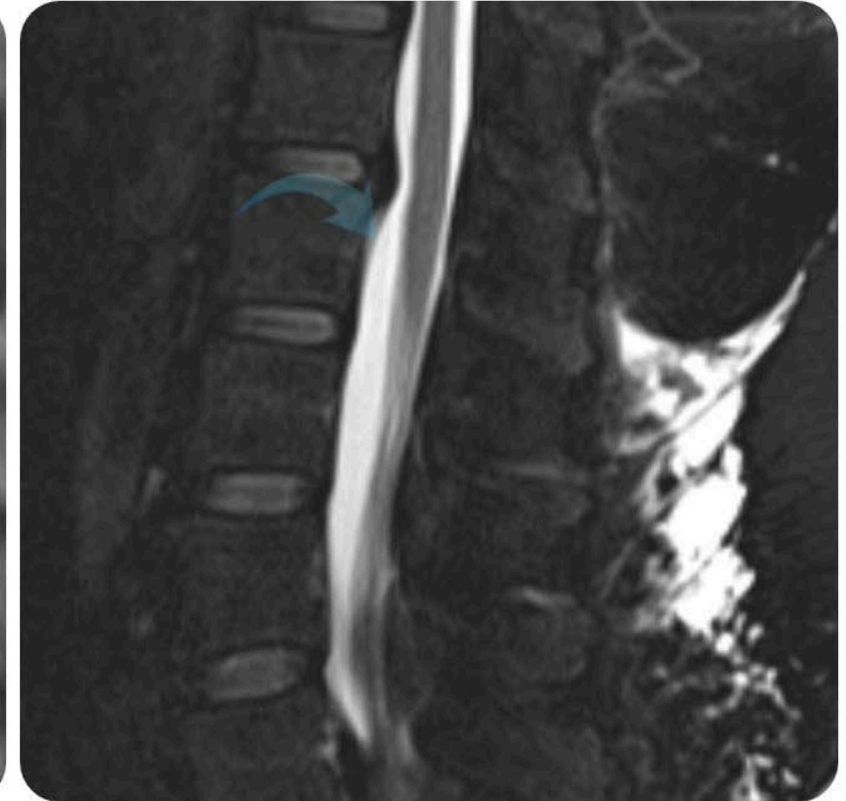
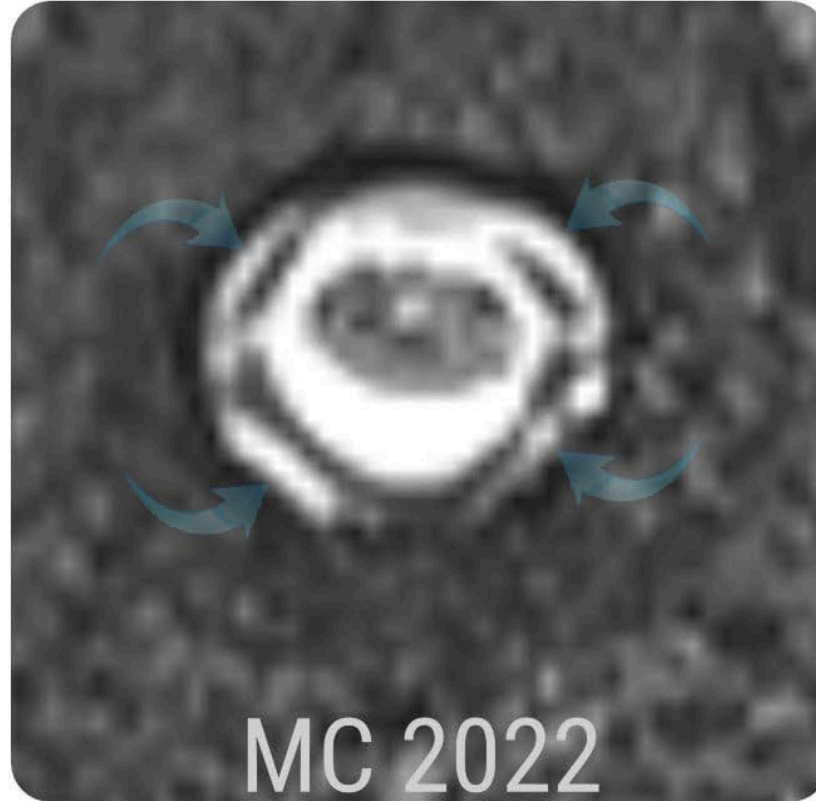
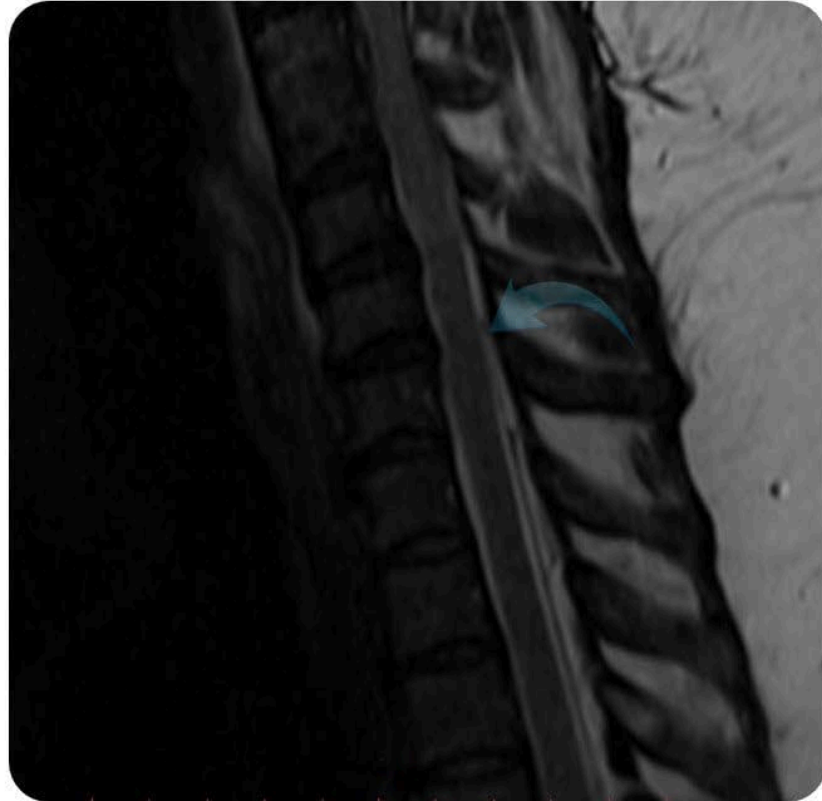A woman with long dark hair, wearing a white lab coat, is holding a white tablet. The tablet screen is black with the word "SYMPTOMS" written in large, bold, white capital letters. She has red nail polish on her fingers.

SYMPTOMS

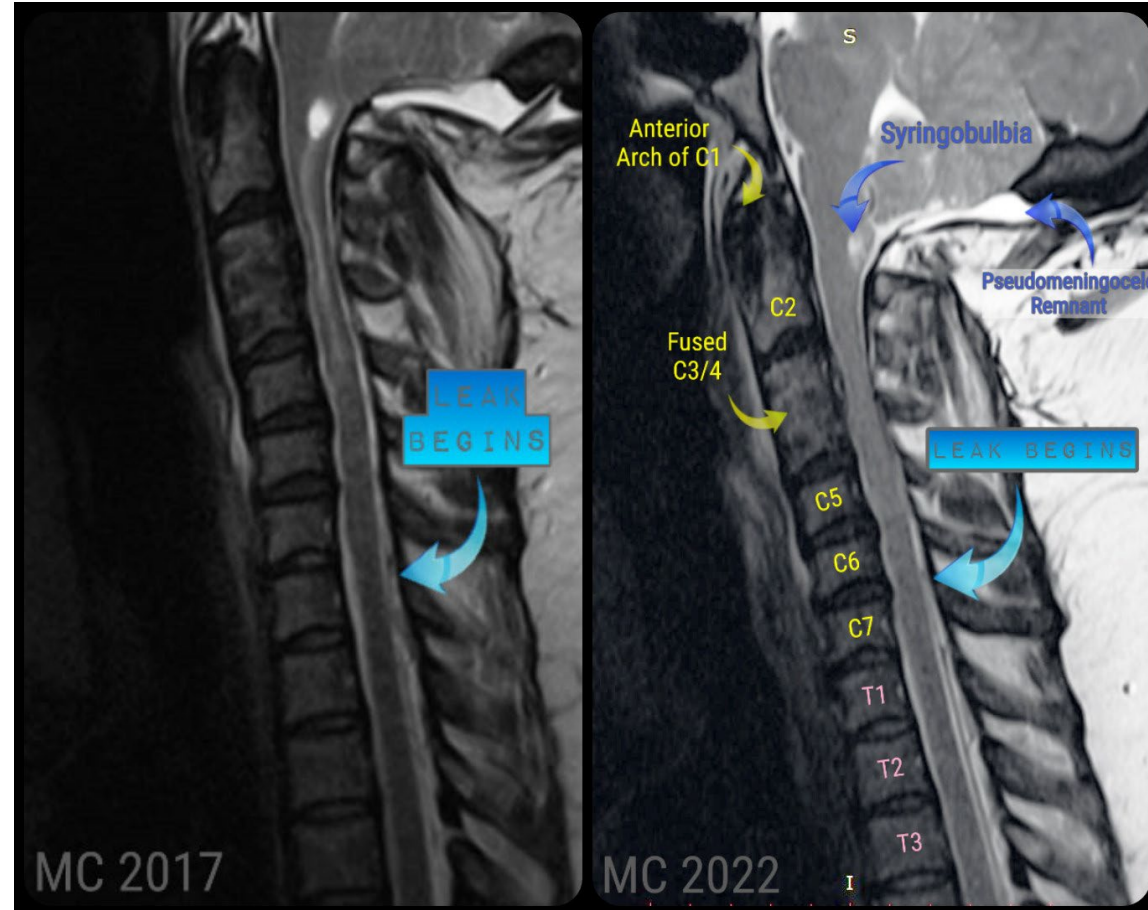
IH/IIH SYMPTOMS

- ✓ Positional Pressure Headaches that are worse when laying down and relieved from being upright
- ✓ Accompanied by pressure behind the eyes (much like a sinus headache)
- ✓ Blurred, fleeting, dimmed, and/or double vision; transient visual obscurations; blindness
- ✓ Pulsatile Tinnitus
- ✓ Hormonal problems that may or may not be evident in thyroid tests.
- ✓ Neck pain/stiffness/spasms as tonsils prolapse

SPINAL LEAK



LEAK PRESENT IN 2017



Tethered Cord Syndrome (TCS) is one of those pathological conditions.

